

Analysis of Best Management of Proliferative Sickle Cell Retinopathy in African Population- A Retrospective Analytical Study

FRANCIS KWASI OBENG¹, VIPAN KUMAR VIG², PREETAM SINGH³, RAJBIR SINGH⁴, YAO AHONON⁵



ABSTRACT

Introduction: Visual impairment in Proliferative Sickle Cell Retinopathy (PSCR) starts with neovascularisation. Treatment armamentaria including diathermy, retinopexy, Autoinfarction (AI), surgical procedures and intravitreal Anti-Vascular Endothelial Growth Factors Injections Monotherapy (AEGFM) have been applied. Some outcomes led to blindness but data on how effective AEGFM is in treating PSCR is lacking in several publications.

Aim: To assess outcome and complication profile of large series of patients who underwent AEGFM after being diagnosed with PSCR.

Materials and Methods: This was a retrospective analytical study conducted in October 2020 on records of 40 patients who underwent AEGFM and other treatment on account of PSCR at Department of Ophthalmology, 37 Military Hospital, Accra, Ghana. The records were reviewed retrospectively for visual outcomes and complications. Patients' demographic data, indications of

treatment, best corrected preoperative and postoperative visual acuities, complications of surgery and length of follow-up were collected and analysed using chi-square and paired t-tests.

Results: A total of 80 eyes of 40 patients (36 males and four females) were identified. Mean age during AEGFM (72 eyes) and vitreoretinal surgery (eight eyes) was 31.7±9.3 years (range 26-56 years) with mean follow-up period of 6±1 years (range 5-7 years). A total of 70 (87.5%), 2 (2.5%) and 8 eyes (10%) had improvement, maintenance and worsening of final visual acuities, respectively. A total of 8 (16%) eyes developed postoperative complications from retinal surgeries with Proliferative Vitreoretinopathy (PVR) being the most common. Forty (50%) eyes with old retinal Laser Photocoagulation (LP) scars reported with fresh elevated Sea Fans (SF) and Vitreous Haemorrhage (VH). LP is therefore a major source of SF formation and VH in PSCR.

Conclusion: AEGFM is better treatment than other available modalities in management of undetached PSCR.

Keywords: Laser photocoagulation, Proliferative vitreoretinopathy, Retinal neovascularisation, Sea fans, Vitreous haemorrhage

INTRODUCTION

Globally, African continent which is grappling with malaria has recorded highest prevalence and incidence of Sickle Cell Disease (SCD) due to which PSCR develops [1]. This is so because patients who have traits of SCD get protection against falciparum malaria which is a major cause of death. These traits favour survival of the host and transmission of abnormal haemoglobin (Hb) gene to future generations [2]. Left untreated, the natural history of SF formed from Sickle Cell Disease (SCD) may be marked by VH, tractional or rhegmatogenous Retinal Detachment (RD) [3], all of which can lead to blindness. In prevention of blindness, several treatment approaches have been applied in the past and present with poor outcomes. Notable amongst them are diathermy, retinopexy, Autoinfarction (AI) and surgical procedures. A paradigm shift in management of PSCR is emerging in form AEGFM.

Treatment of SF with diathermy was relegated to the background several decades ago because it caused a lot of uveitides and anterior segment ischaemia [4]. LP, either xenon arc or argon, has been used to destroy neovascular tissue for several decades [5,6]. However, it has several limitations and complications. Retinal haemorrhage, VH, cataract, hyphaema and corneal scars act as limitations to successful LP. Complication profile of LP are classified into intraocular and extraocular. Whereas the former comprises retinal haemorrhage, VH [6], choroidal ischaemia [7], choroidovitreous neovascularisation [6,8], choroidal rupture, choroidal haemorrhage, rupture of Bruch's membrane, retinal scars, enlarged retinal scars [9], reduced macular sensitivity, optic disc atrophy and recurrence of retinal new vessels, the latter entails reduction in visual field, poor sight, inadequate dark adaptation, nyctalopia and sometimes transient accommodative paraesis.

The advantage cryopexy has over LP is that it can be used in small pupils and opaque media to achieve same outcome as LP. However, it is not widely used because it is limited to only anterior retina. Its major complications are retinal tears and Tractional Retinal Detachment (TRD) [10]. The natural process through which neovascular complex regresses without any intervention is known as AI [11]. It, therefore, occludes SF more elegantly than retinopexy reflecting clinical improvement as VH and possible RD are rendered less likely. However, had AI been reliable enough a mechanism, then there would have been neither the need to propose any treatment for PSCR nor its classification up to stage V characterised by RD. Additionally, no patient would ever be blind from PSCR. According to Serjeant, AI is more common in genotype SS [12], a group which is least prone to PSCR rendering the whole assertion paradoxical and scientifically negligible.

The major technical problem associated with Pars Plana Vitrectomy (PPV) is manipulation of already ischaemic and fragile extreme retinal periphery, where iatrogenic breaks, cataract or vitreous skirt may occur [13]. Hyphaema, residual VH and secondary glaucoma are complications that are difficult to manage [14]. Use of Scleral Buckle (SB) to treat RD is challenging because there is great chance that these patients will develop anterior segment ischemia that may progress to phthisis bulbi ultimately [15]. What makes surgery a more cumbersome method is, that, whereas the patient might need transfusion of healthy red cells to replace the sickled erythrocytes, the surgeon should avoid direct-acting sympathomimetics and post-synaptic alpha-adrenergic receptor agonists like phenylephrine in dilating the pupils because they can enhance sickling through vasoconstriction [16,17]. Cold temperature in theatre for many hours of surgery can also trigger sickling and complicate the procedure [16,17].

To date, a few published case series have shown favourable results when AEGFM is utilised in management of undetached PSCR [18,19]. To the best of our knowledge, this is the first time such new treatment is being assessed in Africans. The purpose of the study was to analyse outcome and complication profile of patients in Sub-Sahara Africa who underwent AEGFM after being diagnosed with PSCR.

MATERIALS AND METHODS

This is an analytical retrospective study carried out in October 2020 to review medical records of 74 patients (148 eyes) who underwent AEGFM from September 2013 to September 2020 and other forms of retinal treatment after being diagnosed with PSCR at Department of Ophthalmology, 37 Military Hospital, Accra, Ghana.

These patients had a minimum follow-up of 5 years. One experienced Consultant Vitreoretinal and Ophthalmic Surgeon performed all the procedures. Institutional Ethical Approval was acquired for this research and in a broader measure, tenets of Declaration of Helsinki were applied to preserve human rights of participants. Records of those patients who were examined and diagnosed at the retina clinic of 37 Military Hospital in Accra, Ghana from September 2013 to September 2020 were collected.

Inclusion criteria: Patients included in the study were those who were examined and diagnosed at the retina clinic of 37 Military Hospital in Accra, Ghana. Inclusion criteria for AEGFM were eyes with PSCR without TRD and dense VH. Inclusion criteria for surgery were eyes with TRD and dense VH.

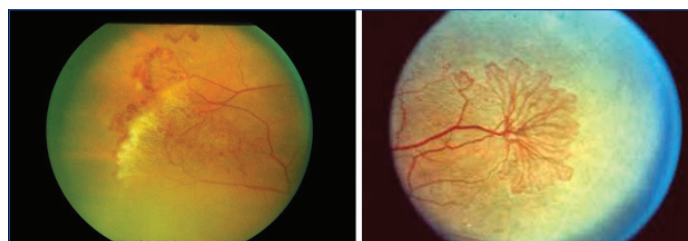
Exclusion criteria: Out of 74 patients whose medical records were reviewed, 34 were excluded from the study because they were either followed up for less than five years or lost to follow-up or did not meet criteria for AEGFM. Exclusion criteria for AEGFM were eyes with retinal tractional bands, RD, painful red eye, conjunctivitis and blind eye.

Some of the patients had been referred from other Sub-Saharan African countries. In addition to general demographic data, information on baseline preoperative visual acuity, indication for procedure, postoperative complications, latest Best Corrected Visual Acuity (BCVA) and indication for any subsequent surgical procedures was collected and analysed.

Procedure

The AEGFM was administered by one Consultant Vitreoretinal and Ophthalmic Surgeon (FKO) under sterile and aseptic conditions in an operation theatre using same procedures in all patients. About 10% povidone iodine was used to clean skin around the eyelids with gauze. Topical anaesthetic drops were administered, the injection site washed with 5% povidone iodine, a lid speculum used, a 30-gauge needle inserted through pars plana and bevacizumab (Avastin, 1.25 mg in 0.05 mL) injected into the vitreous. Other anti-VEGFs (ranibizumab and aflibercept) were used when bevacizumab became scarce. A cotton-tipped applicator was used to apply mild pressure for 15 seconds at the site of injection immediately after needle withdrawal. The eye was then patched after instillation of one drop of 5% povidone iodine onto the ocular surface. Patches were removed two hours after the procedure and patients, reviewed one day and one week after injection. A treat and extend approach was used in all patients with total number of injections in an eye ranging from 3 to 6 depending on severity of PSCR [Table/Fig-1,2] on first examination.

LP technique used in the study consisted of sectorial treatment of SF with argon. Retinal surgeries were performed in patients who developed RD. It consisted of three port PPV, posterior vitreous detachment induction, membrane segmentation, membrane delamination, fluid air exchange, endolaser, 6 o'clock iridectomy, silicone oil injection into the vitreous cavity and anterior retinal cryotherapy under sterile and aseptic conditions. Snellen BCVA was converted into logarithm of minimum angle of resolution (logMAR) units in order to get better statistical



[Table/Fig-1]: Sea fan lesions in PSCR. **[Table/Fig-2]:** Sea fan lesions in PSCR. (Images from left to right)

analysis. Patients whose visual acuities were hand movement were assigned equivalence of 1.7 logMAR units.

STATISTICAL ANALYSIS

Paired t-test was used for normally distributed variables. All tests were considered statistically significant, if, p-value was 0.05 or less. Chi-square test and paired t-test with Statistical Package for Social Sciences (SPSS) and Graphpad software were used, respectively.

RESULTS

Although all patients were sickling positive with genotype SC, only 8 (20%) knew their sickling and genotype status. A total of 80 eyes of 40 patients (36 males and four females) were identified. Mean age during AEGFM (72 eyes) and vitreoretinal surgery (eight eyes) was 31.7±9.3 years (range 26-56 years), with mean follow-up period of 6±1 years (range 5-7 years).

BCVA did not change in patients who had initial good BCVA, but individuals with VH without RD and initial poor visual acuities had remarkable improvement in their sight after AEGFM. Mean pretreatment BCVA was 0.57±0.50 logMAR units which depended on stage and severity of disease. The mean difference between final post and pretreatment visual acuity was 0.50±1.0 logMAR units which was statistically significant ($p < 0.005$).

[Table/Fig-3] summarises visual outcomes of different modalities of treatment offered. In all 87.5% of eyes had improvement, 2.5% maintenance and 10% worsening of final post-treatment visual acuities compared to pretreatment measurement.

BCVA quality	Procedure	Number of eyes (%)
Maintenance	AEGFM	2 (2.5)
Improvement	AEGFM	70 (87.5)
Worsening	Retinal Surgery	8 (10)

[Table/Fig-3]: Shows BCVA after procedures.

BCVA: Best corrected visual acuity; AEGFM: Antivascular endothelial growth factors monotherapy

Based on results in [Table/Fig-4], there was statistically significant difference in the means of pre and post-treatment visual acuities; thus an improvement in the AEGFM visual acuity.

Difference of visual acuity	Paired differences				T	Df	Sig. (2-tailed) p-value	
	Mean difference (log-MAR units)	Std. deviation (logMAR units)	Std. error mean (log-MAR units)	95% confidence interval of the difference				
				Lower				Upper
Decimal (Pretreatment) - Decimal (Post-treatment)	-0.514	0.449	0.054	-0.621	-0.407	-9.59	69	<0.05

[Table/Fig-4]: Paired samples test showing significant difference in pre and post-treatment visual acuities using AEGFM.

The underlying vitreoretinal diseases which led to AEGFM included peripheral SF neovascularisation without retinal or VH (n=30 eyes; 37.5%) and VH with sector LP scars (n=40 eyes; 50%). Eight eyes (10%) were only observed without any therapeutic intervention because their visual acuities were nil perception of light each on account of PVR secondary to previously failed Vitreoretinal Surgery

(VRS) performed by other surgeons due to combined tractional and rhegmatogenous RD. The remaining 2 eyes (2.5%) from two patients had not had any form of ophthalmic examination. They had gone phthisical when examined for the first time.

In all 30 of 80 eyes whose initial treatments was AEGFM did not develop any complication [Table/Fig-5]. The most common complication was recurrent retinal new vessels formation from previous retinal LP. All the 40 eyes whose previous treatment was retinal LP later developed recurrent new vessels. This complication was corrected with AEGFM. The two eyes which went through autoinfarction (AI) became totally blind. Out of eight eyes which had VRS, all of them had one form of complication or the other, resulting in blindness at last follow-up visit. Development of cataract was not ascribable to PSCR, since its ischaemia protects crystalline lens against cataractogenesis. Cataract formation was due to VRS.

Serial no.	Intervention	Number of eyes out of 80	Complication	Complication N (%) for each procedure	Management
1	AEGFM	30	None	0 (0%)	Observation
2	Retinal LP	40	Recurrent Retinal New Vessels	40 (100%)	AEGFM
3	Autoinfarction	2	Phthisis Bulbi	2 (100%)	Observation
4	Vitreoretinal surgery	4	Stage 4 Proliferative Vitreoretinopathy	4 (100%)	Observation
5	Vitreoretinal surgery	2	Recurrent Vitreous Haemorrhage	2 (100%)	AEGFM
6	Vitreoretinal surgery	2	Cataract	2 (100%)	Cataract surgery

[Table/Fig-5]: Complications of different modalities of PSCR treatment and their management.

PSCR: Proliferative sickle cell retinopathy; AEGFM: Antivascular endothelial growth factors monotherapy; LP: Laser photocoagulation

DISCUSSION

Anti-Vascular Endothelial Growth Factors Injections Monotherapy is emerging as the best modality of treatment in management of undetached PSCR although it has not gained popularity due to little research on this novel therapy. In the present study, 30 eyes with PSCR were originally and successfully treated with AEGFM. Additionally, all 40 eyes which had retinal LP as original treatment developed complications which were eventually managed with AEGFM as shown [Table/Fig-5] above. On the average, the present study revealed that an eye with undetached PSCR needed at least three treatment sessions using treat and extend approach. Scarcity of bevacizumab led to use of ranibizumab in five eyes and aflibercept in six eyes all of which gave good outcomes. After third injection with bevacizumab, an eye did not respond to treatment. Subsequently, treatment was changed to aflibercept and the new vessels regressed. Similarly, two eyes which were started on aflibercept did not respond well to treatment. After bevacizumab was initiated in their management, those eyes responded to treatment. It has, therefore, not been established in the study that one anti-VEGF is superior to another.

Siqueira RC et al., published an article in which bevacizumab was used in regression of SF together with LP [18]. This method was used because the patient refused to undergo PPV. Another article was published in which bevacizumab monotherapy was used in treatment of PSCR [19]. They treated five eyes, four of which had VH. The fifth eye had SF without VH. Two of the eyes had recurrent VH within 13 years of follow-up. The researchers, however, were sceptical about frequency and interval of treatment [19]. In all cases, there have not been reported complications with use of bevacizumab except one case in which Babalola OE observed hyphaema in their patient after treatment [20]. Albeit some researchers used bevacizumab, Mitropoulos PG et al., used ranibizumab to achieve same treatment efficacy [21]. Their patients had regression of VH and SF without complications [21].

Use of AEGFM in treatment of undetached PSCR is based on pathogenesis of the disease. Ischaemia induced new retinal vessel formation is regulated by Vascular Endothelial Growth Factor (VEGF) and their Receptors (VEGFRs) which include Placental Growth Factor (PIGF), angiopoietin and Tie receptors, Platelet-Derived Growth Factor-B (PDGF-B), Stromal-Derived Factor-1 (SDF-1), Hypoxia Inducible Factor-1 (HIF-1) and signals from extracellular matrix [22]. Increased VEGF transcription and upregulation of angiogenesis re-establishes oxygen and nutrition supply to tissues affected by hypoxia [23]. VEGF also contributes to inflammatory process by inducing expression of Vascular Cell Adhesion Molecule-1 (VCAM-1) to enhance leukocyte recruitment and endothelial cell adhesion leading to blood retinal barrier breakdown and new vessel formation [24]. Anti-VEGF is therefore, used to inhibit the release and functions of VEGF.

Ocular complications associated with anti-VEGF use may include ablation of choriocapillaris and vision loss [25], worsening of Geographic Atrophy (GA) [26] and accelerated photoreceptor apoptosis [27]. Anti-VEGF may have systemic complications which may result from minute escape of the substance from vitreous to systemic circulation. These may include vascular hyperpermeability, arterial hypertension, thromboembolic events, left ventricular dilatation and contractile dysfunction as well as heart failure [28-30]. All these complications are found in non Africans. None of the patients in the present study developed any of these ocular or systemic complications. Melanin, therefore, may have a protective role against side effects from anti-VEGF.

A Cochrane review showed poor results when 341 eyes with PSCR were managed with LP [31]. According to Rednam KR et al., 29 participants who received LP developed fresh SF after nine years of follow-up [32]. A study from Brazil showed initial regression of SF with LP, a success which was marred by development of new SF after several months of follow-up [33,34]. Interestingly, some authors of studies which had initial success with LP did not report on complications of same, a bias which should be analysed. Additionally, a study published by Jampol LM and Goldberg MF, established that even after a successful LP, retinal tears and rhegmatogenous RD may occur [35].

A research which associated age and genotype conducted in Jamaica revealed that the mean age of patients who had AI was 39.2 in genotype SS and 35.2 years genotype SC [36]. Whereas AI occurs less frequently in patients who are younger than 40 years, it is more common in patients who are older than age 40 years especially if they have genotype SS [37]. AI occurs on the average two years after appearance of SF in as many as 60% of patients [11,36]. A research published by Condon PI and Serjeant GR, revealed 12% of AI cases went blind [36]. Another study conducted by Moriarty BJ et al., revealed 10% of untreated eyes lost visual acuity over ten years [38]. In the present study, two eyes went phthisical from AI because the patients in question did not have access to a retinal specialist. If it were reliable, no literature would have extended pathogenesis of PSCR beyond stage 3. It can, therefore, categorically be stated from evidences gathered above that AI is not reliable and that interventional treatment is important in management of PSCR.

Pars Plana Vitrectomy may be required when SF lead to very dense VH and or RD [39]. According to Chen RW et al., surgical complications from PSCR can happen in 50% of patients [40]. Another study conducted by McKinney CM et al., revealed that complications of PSCR may regress and reappear even after successful PPV [41]. In the present study, all eight eyes which had PPV ended up with nil perception of light as visual acuity at last follow-up.

Limitation(s)

The retrospective nature, single-centre focus, variable follow-up lengths, and the fact that only one Consultant Vitreoretinal and Ophthalmic Surgeon performed all the procedures limited the study.

CONCLUSION(S)

There have been several treatment modalities in management of undetached PSCR whose natural history is blindness in the Sub-Saharan African geographical area. Being the cheapest method of treatment, LP is commonly used but it is associated with several complications many of which are causes of blindness. The present research has revealed that when undetached, PSCR responds very well to AEGFM which is a novel treatment and at the same time leaves no complications in management of the disease. Management with AEGFM can be (pro re nata) PRN or treat and extend depending on each patient and their clinical presentation. One major difficulty is cost involved, but it is relatively very cheap compared to blindness from other methods of management. Measures should be taken to prevent RD because the present research has proved that all retinæ which were detached and had retinal surgeries became blind.

REFERENCES

- [1] Fox PD, Dunn DT, Morris JS, Serjeant GR. Risk factors for proliferative sickle retinopathy. *Br J Ophthalmol*. 1990;74(3):172-76.
- [2] Taylor SM, Parobek CM, Fairhurst RM. Haemoglobinopathies and the clinical epidemiology of malaria: A systematic review and meta-analysis. *Lancet Infect Dis*. 2012;12(6):457-68.
- [3] Moriarty BJ, Acheson RW, Condon PI, Serjeant GR. Patterns of visual loss in untreated sickle cell retinopathy. *Eye (Lond)*. 1988;2 (pt 3):330-35.
- [4] Condon PI, Serjeant GR. Photocoagulation and diathermy in the treatment of proliferative sickle retinopathy. *Br J Ophthalmol*. 1974;58(7):650-62.
- [5] Castro O. Management of sickle cell disease: Recent advances and controversies. *Br J Haematol*. 1999;107(1):02-11.
- [6] Rodrigues M, Kashiwabuchi F, Deshpande M. Expression pattern of HIF-1 α and VEGF supports circumferential application of scatter laser for proliferative sickle retinopathy. *Invest Ophthalmol Vis Sci*. 2016;57(15):6739-46.
- [7] Goldbaum MH, Galinos SO, Apple DJ, Asdourian GK, Nagpal K, Jampol L, et al. Acute choroidal ischemia as a complication of photocoagulation. *Archives of Ophthalmology*. 1976;94(6):1025-35.
- [8] Galinos SO, Asdourian GK, Woolf MB, Goldberg MF, Busse BJ. Choroido-vitreous neovascularisation after argon laser photocoagulation. *Archives of Ophthalmology*. 1975;93:524-30.
- [9] Schatz H, Madeira D, McDonald HR, Johnson RN. Progressive enlargement of laser scars following grid laser photocoagulation for diffuse diabetic macular edema. *Arch Ophthalmol*. 1991;109(11):1549-51.
- [10] Goldbaum MH, Fletcher RC, Jampol LM, Goldberg MF. Cryotherapy of proliferative sickle retinopathy, II: Triple freeze-thaw cycle. *Br J Ophthalmol*. 1979;63(2): 97-101.
- [11] Luty GA et al. Sickle cell retinopathy and hemoglobinopathies. In: Joussem AM et al. *Retinal Vascular Diseases*. Berlin: Springer-Verlag; 2007.
- [12] Lemaire C, Lamare Y, Lemonne N, Waitz X, Chahed S, Cabot F et al. Severe proliferative retinopathy is associated with blood hyperviscosity in sickle cell hemoglobin-C disease but not in sickle cell anemia; *Clin Hemorheol Microcirc*. 2013;55(2):205-12.
- [13] Jampol LM, Green JL Jr, Goldberg MF, Peyman GA. An update on vitrectomy surgery and retinal detachment repair in sickle cell disease. *Arch Ophthalmol*. 1982;100(4):591-93.
- [14] Goldberg MF. The diagnosis and treatment of secondary glaucoma after hyphema in sickle cell patients. *Am J Ophthalmol*. 1979;87(1):43-49.
- [15] Ryan SJ, Goldberg MF. Anterior segment ischemia following scleral buckling in sickle cell hemoglobinopathy. *Am J Ophthalmol*. 1971;72(1):35-50.
- [16] Koshy M, Weiner SJ, Miller ST, Sleeper LA, Vichinsky E, Brown AK, et al. Surgery and anesthesia in sickle cell disease. Cooperative Study of Sickle Cell Diseases. *Blood*. 1985;66(10):3676-84
- [17] de Montalembert M. Management of sickle cell disease. *BMJ*. 2008;337:a1397. Review.
- [18] Siqueira, RC, Costa, RA, Scott, IU, Cintra, LP, Jorge, R. Intravitreal bevacizumab (Avastin) injection associated with regression of retinal neovascularisation caused by sickle cell retinopathy. *Acta Ophthalmol Scand*. 2006;84(6):834-35.
- [19] Cai CX, Linz MO, Scott AW. Intravitreal bevacizumab for proliferative sickle retinopathy: A case series. *Journal of Vitreo Retinal Diseases*. 2018;2(1):32-38.
- [20] Babalola OE. Intravitreal bevacizumab (Avastin) associated with secondary hyphaema in a case of proliferative sickle cell retinopathy. *BMJ Case Rep*. 2010;2010. pii: bcr11.2009.2441. Intravitreal ranibizumab for stage IV proliferative sickle cell retinopathy: A first case report. *Case reports in Ophthalmological Medicine* 2014:682583.
- [21] Mitropoulos PG, Chatziralli IP, Parikakis EA, Peponis VG, Amariotakis GA, Moschos MM. Intravitreal ranibizumab for stage IV proliferative sickle cell retinopathy: A first case report. *Case reports in Ophthalmological Medicine*. 2014;2014:682583.
- [22] Campochiaro PA. Molecular pathogenesis of retinal and choroidal vascular diseases. *Prog Retin Eye Res*. 2015;49:67-81. Doi: 10.1016/j.preteyeres.2015.06.002.
- [23] Kim M, Lee C, Payne R, Yue BYJT, Chang JH, Ying H. Angiogenesis in glaucoma filtration surgery and neovascular glaucoma: A review. *Surv Ophthalmol*. 2015;60(6):524-35.
- [24] Kaur C, Foulds WS, Ling EA. Hypoxia-ischemia and retinal ganglion cell damage. *Clin Ophthalmol*. 2008;2(4):879-89.
- [25] Kurihara T, Westenskow PD, Bravo S, Aguilar E, Friedlander M. Targeted deletion of Vegfa in adult mice induces vision loss. *J Clin Invest*. 2012;122(11):4213-17.
- [26] Gemenetzi M, Lotery AJ, Patel PJ. Risk of geographic atrophy in age-related macular degeneration patients treated with intravitreal anti-VEGF agents. *Eye*. 2016;31(1):01-09.
- [27] Saint-Geniez M, Kurihara T, Sekiyama E, Maldonado AE, D'Amore PA. An essential role for RPE-derived soluble VEGF in the maintenance of the choriocapillaris. *Proc Natl Acad Sci USA*. 2009;106(44):18751-56.
- [28] Chen ZI, Ai DI. Cardiotoxicity associated with targeted cancer therapies. *Mol Clin Oncol*. 2016;4(5):675-81.
- [29] Izumiya Y, Shiojima I, Sato K, Sawyer DB, Colucci WS, Walsh K. Vascular endothelial growth factor blockade promotes the transition from compensatory cardiac hypertrophy to failure in response to pressure overload. *Hypertension*. 2006;47(5):887-93.
- [30] Choueiri TK, Mayer EL, Je Y, Rosenberg JE, Nguyen PL, Azzi GR, et al. Congestive heart failure risk in patients with breast cancer treated with bevacizumab. *J Clin Oncol*. 2011;29(6):632-38.
- [31] Myint KT, Sahoo S, Thein AW, Dhibi HA, Schellini S, Malik R et al. Laser therapy for retinopathy in sickle cell disease. *Cochrane Database Syst Rev*. 2015;(10):CD010790. doi.org/10.1102/14651858.CD010790.
- [32] Rednam KR, Jampol LM, Goldberg MF. Scatter retinal photocoagulation for proliferative sickle cell retinopathy. *Am J Ophthalmol*. 1982;93:594-99.
- [33] Farber MD, Jampol LM, Fox P, Moriarty BJ, Acheson RW, Rabb MF, et al. A randomized clinical trial of scatter photocoagulation of proliferative sickle cell retinopathy. *Arch Ophthalmol*. 1991;109(3):363-67.
- [34] Jampol LM, Condon P, Farber M, Rabb M, Ford S, Serjeant G. A randomized clinical trial of feeder vessel photocoagulation of proliferative sickle cell retinopathy. I. Preliminary results. *Ophthalmology*. 1983;90(5):540-45.
- [35] Jampol LM, Goldberg MF. Retinal breaks after photocoagulation of proliferative sickle cell retinopathy. *Arch Ophthalmol*. 1980;98(4):676-79.
- [36] Condon PI, Serjeant GR. Behaviour of untreated proliferative sickle retinopathy. *British Journal of Ophthalmology*. 1980;64(6):404-11.
- [37] Fox PD, Vessey SJ, Forshaw ML, Serjeant GR. Influence of genotype on the natural history of untreated proliferative sickle retinopathy- an angiographic study. *Br J Ophthalmol*. 1991;75(4):229-31.
- [38] Moriarty BJ, Acheson RW, Condon PI, Serjeant GR. Patterns of visual loss in untreated sickle cell retinopathy. *Eye (Lond)* 1988;2(Pt 3):330-35.
- [39] Williamson TH, Rajput R, Laidlaw DA, Mokete B. Vitreoretinal management of the complications of sickle cell retinopathy by observation or pars plana vitrectomy. *Eye*. 2009;23:1314-20.
- [40] Chen RW, Flynn HW Jr, Lee WH, Parke DW 3rd, Isom RF, Davis JL, et al. Vitreoretinal management and surgical outcomes in proliferative sickle retinopathy: A case series. *Am J Ophthalmol*. 2014;157:870-75.
- [41] McKinney CM, Siringo F, Olson JL, Capocelli KE, Ambruso DR, Nuss R. Red cell exchange transfusion halts progressive proliferative sickle cell retinopathy in a teenaged patient with hemoglobin SC disease. *Pediatr Blood Cancer*. 2015;62(4):721-23.

PARTICULARS OF CONTRIBUTORS:

1. Consultant Vitreoretinal and Ophthalmic Surgeon, Department of Ophthalmology, 37 Military Hospital, Accra, Ghana.
2. Consultant Vitreoretinal and Ophthalmic Surgeon, Department of Ophthalmology, Sadar Bagadur, Dr. Sohan Singh Eye Hospital, Amritsar, Punjab, India.
3. Consultant Vitreoretinal and Ophthalmic Surgeon, Department of Ophthalmology, Sadar Bagadur, Dr. Sohan Singh Eye Hospital, Amritsar, Punjab, India.
4. Consultant Vitreoretinal and Ophthalmic Surgeon, Department of Ophthalmology, Sadar Bagadur, Dr. Sohan Singh Eye Hospital, Amritsar, Punjab, India.
5. Biostatistician, Department of Public Health, Korle-Bu Teaching Hospital, Accra, Greater Accra, Ghana.

NAME, ADDRESS, E-MAIL ID OF THE CORRESPONDING AUTHOR:

Dr. Francis Kwasi Obeng,
Consultant Vitreoretinal and Ophthalmic Surgeon, Department of Ophthalmology,
37 Military Hospital, Accra, Greater Accra, Ghana.
E-mail: Obengfranzis@gmail.com

PLAGIARISM CHECKING METHODS: [Jain H et al.]

- Plagiarism X-checker: Feb 04, 2021
- Manual Googling: Oct 26, 2021
- iThenticate Software: Nov 18, 2021 (14%)

ETYMOLOGY: Author Origin

AUTHOR DECLARATION:

- Financial or Other Competing Interests: None
- Was Ethics Committee Approval obtained for this study? Yes
- Was informed consent obtained from the subjects involved in the study? Yes
- For any images presented appropriate consent has been obtained from the subjects. Yes

Date of Submission: **Jan 26, 2021**

Date of Peer Review: **Apr 07, 2021**

Date of Acceptance: **Nov 23, 2021**

Date of Publishing: **Feb 01, 2022**